

Diagnosis of post-traumatic complex regional pain syndrome of the hand: current role of sympathetic skin response and three-phase bone scintigraphy

A Pankaj, PP Kotwal, R Mittal

Department of Orthopedics, All India Institute of Medical Sciences, Ansari Nagar, New Delhi, India

KK Deepak

Department of Physiology, All India Institute of Medical Sciences, Ansari Nagar, New Delhi, India

CS Bal

Department of Nuclear Medicine, All India Institute of Medical Sciences, Ansari Nagar, New Delhi, India

ABSTRACT

Purpose. To evaluate the role of sympathetic skin response (SSR) and three-phase bone scintigraphy (TPBS) in the diagnosis of complex regional pain syndrome (CRPS).

Methods. 60 patients with CRPS of the hand were recruited. TPBS was performed using a bolus injection of 20 mCi of Tc-99m methylene diphosphonate in an antecubital vein and blood flow (first phase) image, blood pool (second phase) image, and delayed (third phase) image obtained. Patients were considered to have CRPS when the blood pool and blood flow images showed diffuse asymmetric uptake, or when the delayed image indicated increased asymmetric periarticular uptake. SSR was measured simultaneously in the affected and unaffected hands. Standard surface electromyogram disc electrodes were applied to the palm and dorsum of both hands. Electrical stimuli were applied to the skin at the base of little and ring fingers of the

unaffected hand. Patients were considered abnormal when response was absent or the peak-to-peak amplitude was <50% of the contralateral hand in at least 2 readings.

Results. The delayed phase of TPBS tested positive in all; the first and second phases tested positive in 54 (90%) and 56 (93%) of the patients, respectively. Four of the 6 patients with a negative first phase had had symptoms persisting for more than 6 months, and the other 2 for about 3 to 6 months. No patient presenting within 3 months had a negative scan. SSR was absent in 16 (27%) patients and normal in 44 (73%). 11 (79%) of 14 patients who presented more than 6 months after symptom onset displayed an abnormal SSR, while only 10% of those presenting within 3 to 6 months and 11% of those presenting within 3 months had an abnormal SSR. 12 (75%) of the 16 patients with abnormal SSR had associated decreased sweating, compared with 2 (4.5%) of the 44 patients with a normal SSR.

Conclusion. TPBS is a very sensitive corroborative test to confirm the clinical suspicion of CRPS during the initial stages, but not in late cases. SSR can be used

to document the sympathetic dysfunction in cases having an associated sweating abnormality and may have some diagnostic value in late cases of CRPS, when TPBS is less reliable.

Key words: complex regional pain syndromes; galvanic skin response; hand; radionuclide imaging; reflex sympathetic dystrophy

INTRODUCTION

First described in 1864 by Mitchell,¹ reflex sympathetic dystrophy (RSD), or complex regional pain syndrome (CRPS) as it is now called,² has been a topic of debate and research.³⁻⁷ It is a distinct symptom complex characterised by refractory pain, swelling, limitation of movement, vasomotor instability, trophic skin changes, and patchy demineralisation of the bone (Fig 1).^{2,8-14} Disorders underlying the CRPS include fractures, infection, peripheral neuropathy, central nervous system abnormalities, cervical osteoarthritis, and myocardial infarction.^{15,16}

Although diagnosis of CRPS is usually made by clinical examination, in the last decade a number of objective tests have been devised to confirm this pathophysiologically perplexing condition.^{3,17-21} Three-phase bone scintigraphy (TPBS) has been widely used to diagnose CRPS.^{3,17,20-22} The affected extremity has markedly increased activity with periarticular accentuation in all 3 phases of the scan.^{3,15,16,21} The sensitivity of TPBS in diagnosing CRPS varies from 54 to 100%.^{20,23} Measurement of the increased cutaneous blood flow using laser Doppler flowmetry,⁶ measurement of skin temperature and conductance, as well as response to sympathetic blockade, and intravenous phentolamine appear to be less reliable tests.¹

Sympathetic dysfunction is considered a main pathophysiological cause of this condition.^{6,17,18,24} Diagnosis of CRPS can be confirmed by symptoms of sympathetic over-activity and the response to adequate sympathetic blockade. Nonetheless, an objective means of assessment is needed to diagnose early-stage sympathetic dysfunction with vague symptomatology. Sympathetic skin response (SSR) is used to measure the changes in the electrical activity of sweat glands following sympathetic stimulation.²⁵ SSR is a transient change in the electrical potential of the skin, reflexively evoked by a variety of stimuli.²⁵ The efferent arm of the reflex involves sympathetic nerve fibres, which innervate eccrine sweat glands in the skin. The response is absent/abnormal if the patients have sympathetic nerve fibre diseases such

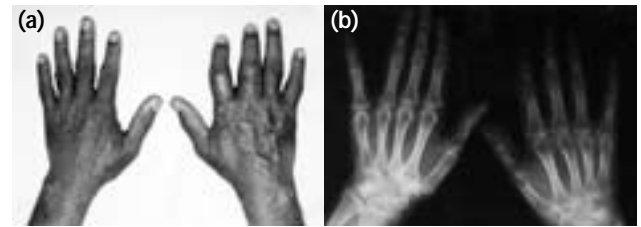


Figure 1 Complex regional pain syndrome of the right hand: (a) clinical characteristics and (b) anteroposterior radiograph showing periarticular osteopenia and patchy demineralisation of the bone.

as peripheral neuropathies with prominent dysautonomic features. There are few reports about SSR abnormalities in patients with CRPS.^{4,18,19} This study aimed to assess the sensitivity of SSR and TPBS in the diagnosis of post-traumatic CRPS of the hand.

MATERIALS AND METHODS

Between June 1998 and May 2002 inclusive, 60 consecutive cases of post-traumatic CRPS of the hand were recruited using the criteria described by Mackinnon and Holder.²⁰ The relevant clinical history and findings from thorough physical examination were recorded in a standard proforma. Anteroposterior and lateral radiographs of both hands were obtained.

TPBS was performed following a bolus injection of 20 mCi of Tc-99m methylene diphosphonate into an antecubital vein. Sequential 5-second radionuclide blood flow (first phase) images were obtained for 30 to 40 seconds using a high sensitivity collimeter. Without altering the position of the hands, blood pool (second phase) images were obtained after one to 5 minutes. Delayed (third phase) images were obtained 3 to 4 hours after the injection. All the images were interpreted by the same radiologist. Patients were considered CRPS positive when the blood flow (first phase) and blood pool (second phase) images showed diffuse asymmetric uptake, or when the delayed (third phase) image indicated increased asymmetric periarticular uptake.²³

SSR was measured simultaneously in the affected and unaffected hand. The patient relaxed in a semi-darkened room in a supine position, with ambient temperature controlled at 22 to 25°C. As the response habituates rapidly after repeated stimuli, stimuli were delivered irregularly over an extended period. Standard (Ag-AgCl 10-mm diameter) surface




Figure 2 Sympathetic skin response: (a) normal and (b) abnormal (peak-to-peak amplitude ratio, <50%).

electromyogram (EMG) disc electrodes were pasted on the palm and dorsum of both hands. Single square wave electrical pulses of 0.1 ms duration, 1-2 mA intensity were applied to the skin at the base of little and ring fingers of the unaffected hand. Responses were recorded with a standard EMG apparatus. A response was considered abnormal: i) if absent, defined as not elicited by 4 stimuli of increasing intensity at intervals of at least 60 seconds, or ii) when the peak-to-peak amplitude was <50% of that in the contralateral hand in at least 2 readings (Fig. 2).^{19,25,26}

Results were analysed using Student's *t* test to compare the means between patient groups (patients with CRPS for <3 months vs 3-6 months vs >6 months) with respect to dependent and independent parameters. The Chi squared test was used for the assessment of qualitative variables. A *p* value of <0.05 was considered significant.

Written informed consent was obtained from all patients and the study was approved by the institutional review board.

RESULTS

Patient characteristics are shown in Table 1. 34 (57%) were aged 40 to 60 years, 19 (32%) were ≤20 years, and 7 (12%) were >60 years. The dominant hand was affected with post-traumatic CRPS in 77% of patients and the non-dominant hand in 23%. 40 (67%) patients had a preceding simple (mostly Colles') fracture; 4 (7%) had had crush injuries and compound fractures; 6 (10%) had had previous surgery (biopsy in 4 and release of Dupuytren's contracture in 2); 10 (17%) had other injuries such as soft tissue wrist injury or contusion of the neck and shoulder. 26 (43%) patients presented within 3 months of the onset of symptoms, 20 (33%) within 3 to 6 months, and 14 (23%) after 6 months.

Three-phase bone scintigraphy

All 60 (100%) patients tested positive for CRPS in the delayed (third) phase, while 56 (93%) were positive in the blood pool (second) phase and 54 (90%) in the blood flow (first) phase. Four of the 6 patients who were CRPS negative in the first phase had symptoms persisting for longer than 6 months, and the remaining 2 for 3 to 6 months; none presented within 3 months. The sensitivity of the blood flow (first) phase was 100% in patients presenting within 3 months of the onset, compared with 71% in those whose symptoms had persisted for longer than 6 months (*p*<0.05, Chi squared test; Table 2). There were no significant differences between any other groups.

Sympathetic skin response

The unaffected hands showed a normal response in all patients. 44 (73%) patients had normal SSR and 16 (27%) abnormal in the affected hands. 11 of the 14 patients who presented more than 6 months after the onset of symptoms had an abnormal SSR, compared with 2 of 20 who did so between 3 and 6 months, and 3 of 26 presenting within 3 months (*p*<0.05, Chi squared test; Table 3 and Fig. 3). The differences between groups >6 months and (i) 3-6 months and (ii) <3 months are significant (*p*<0.05, Chi squared test). 75% (12/16) of the patients with an abnormal SSR had associated decreased sweating (anhidrosis), compared with 5% (2/44) among normal SSR patients; the corresponding difference in proportions was statistically significant (*p*<0.001, Chi squared test; Table 4).

DISCUSSION

CRPS is a common but frequently overlooked clinical condition, secondary to even a minor injury to the extremity. It is a distinct symptom complex characterised by refractory pain, swelling, limitation of movement, vasomotor instability, trophic skin changes, and patchy demineralisation of the bone (Fig. 1).^{2,8-14} CRPS was first described by Mitchell¹ in patients with gunshot wounds to the extremity, it can also be secondary to fractures, infection, peripheral neuropathy, central nervous abnormalities, and myocardial infarction.^{15,16}

The diagnosis of CRPS is usually made clinically based on the presence of the symptom complex. A number of objective tests have been devised to diagnose CRPS over the last decade.^{6,17-19} TPBS is one such test, which has become increasingly

Table 1
Patient characteristics and results

Patient No.	Sex/age (years)	Affected side	Preceding event	Duration (months)	Sweating	Three-phase bone scintigraphy*			Sympathetic skin response
						1st phase	2nd phase	3rd phase	
1	M/40	Dominant	Dupuytren release	<3	Decreased	+ve	+ve	+ve	Abnormal
2	M/45	Dominant	Biopsy	3-6	Increased	+ve	+ve	+ve	Normal
3	F/63	Dominant	Colles' fracture	<3	Normal	+ve	+ve	+ve	Normal
4	M/18	Dominant	Crush injury	<3	Increased	+ve	+ve	+ve	Normal
5	F/17	Non-dominant	1st metacarpal fracture	3-6	Increased	+ve	+ve	+ve	Normal
6	F/53	Dominant	Colles' fracture	<3	Increased	+ve	+ve	+ve	Normal
7	F/60	Dominant	Colles' fracture	3-6	Normal	-ve	-ve	+ve	Normal
8	M/45	Dominant	Colles' fracture	<3	Normal	+ve	+ve	+ve	Normal
9	M/65	Dominant	Colles' fracture	>6	Normal	+ve	+ve	+ve	Normal
10	F/19	Non-dominant	5th metacarpal fracture	>6	Decreased	-ve	-ve	+ve	Abnormal
11	M/42	Non-dominant	Phalanx fracture	3-6	Normal	+ve	+ve	+ve	Normal
12	F/52	Dominant	Colles' fracture	<3	Decreased	+ve	+ve	+ve	Abnormal
13	F/59	Non-dominant	Colles' fracture	>6	Normal	-ve	+ve	+ve	Abnormal
14	F/20	Dominant	Biopsy	<3	Increased	+ve	+ve	+ve	Normal
15	M/70	Dominant	Colles' fracture	<3	Normal	+ve	+ve	+ve	Normal
16	M/60	Dominant	Colles' fracture	3-6	Normal	+ve	+ve	+ve	Normal
17	F/55	Non-dominant	Colles' fracture	>6	Decreased	+ve	+ve	+ve	Abnormal
18	M/64	Dominant	Colles' fracture	<3	Increased	+ve	+ve	+ve	Normal
19	M/20	Dominant	Scaphoid fracture	3-6	Normal	+ve	+ve	+ve	Normal
20	M/50	Non-dominant	Colles' fracture	>6	Decreased	-ve	-ve	+ve	Abnormal
21	F/52	Dominant	Colles' fracture	<3	Normal	+ve	+ve	+ve	Normal
22	F/18	Dominant	Biopsy	<3	Increased	+ve	+ve	+ve	Normal
23	F/46	Dominant	Radial styloid fracture	>6	Decreased	+ve	+ve	+ve	Abnormal
24	F/17	Dominant	Crush injury	<3	Normal	+ve	+ve	+ve	Normal
25	M/19	Non-dominant	Others	3-6	Increased	+ve	+ve	+ve	Normal
26	F/48	Dominant	Colles' fracture	<3	Normal	+ve	+ve	+ve	Normal
27	M/20	Non-dominant	Compound fracture	>6	Decreased	+ve	+ve	+ve	Abnormal
28	M/56	Dominant	Colles' fracture	>6	Increased	+ve	+ve	+ve	Normal
29	M/55	Dominant	Colles' fracture	<3	Normal	+ve	+ve	+ve	Abnormal
30	M/63	Dominant	Colles' fracture	3-6	Normal	-ve	+ve	+ve	Normal
31	F/42	Dominant	Colles' fracture	>6	Decreased	+ve	+ve	+ve	Abnormal
32	M/55	Dominant	Colles' fracture	3-6	Decreased	+ve	+ve	+ve	Abnormal
33	F/19	Dominant	5th metacarpal fracture	<3	Increased	+ve	+ve	+ve	Normal
34	M/46	Non-dominant	Dupuytren release	<3	Increased	+ve	+ve	+ve	Normal
35	M/17	Dominant	Others	>6	Normal	+ve	+ve	+ve	Normal
36	M/60	Dominant	Colles' fracture	3-6	Normal	+ve	+ve	+ve	Normal
37	M/67	Dominant	Colles' fracture	<3	Normal	+ve	+ve	+ve	Normal
38	F/55	Dominant	Colles' fracture	>6	Normal	-ve	-ve	+ve	Abnormal
39	F/20	Dominant	Others	<3	Increased	+ve	+ve	+ve	Normal
40	M/45	Non-dominant	Colles' fracture	<3	Increased	+ve	+ve	+ve	Normal
41	F/17	Dominant	Compound fracture	3-6	Increased	+ve	+ve	+ve	Normal
42	F/68	Dominant	Colles' fracture	3-6	Normal	+ve	+ve	+ve	Normal
43	M/43	Dominant	Others	<3	Decreased	+ve	+ve	+ve	Normal
44	F/56	Non-dominant	Colles' fracture	3-6	Normal	+ve	+ve	+ve	Normal
45	F/55	Dominant	Colles' fracture	<3	Normal	+ve	+ve	+ve	Normal
46	F/19	Dominant	Others	>6	Decreased	+ve	+ve	+ve	Abnormal
47	M/45	Non-dominant	Ulnar styloid fracture	3-6	Increased	+ve	+ve	+ve	Normal
48	M/20	Dominant	Others	<3	Normal	+ve	+ve	+ve	Normal
49	M/42	Dominant	Others	3-6	Normal	+ve	+ve	+ve	Normal
50	F/16	Dominant	Others	3-6	Normal	+ve	+ve	+ve	Normal
51	M/45	Dominant	Biopsy	<3	Increased	+ve	+ve	+ve	Normal
52	M/56	Dominant	Colles' fracture	3-6	Normal	+ve	+ve	+ve	Normal
53	F/19	Dominant	Others	<3	Increased	+ve	+ve	+ve	Normal
54	F/58	Non-dominant	Colles' fracture	>6	Decreased	+ve	+ve	+ve	Abnormal
55	M/20	Dominant	Others	3-6	Normal	+ve	+ve	+ve	Normal
56	M/60	Dominant	Colles' fracture	>6	Normal	+ve	+ve	+ve	Abnormal
57	F/56	Dominant	Colles' fracture	<3	Decreased	+ve	+ve	+ve	Normal
58	F/20	Non-dominant	Phalanx fracture	3-6	Decreased	+ve	+ve	+ve	Abnormal
59	M/52	Dominant	Colles' fracture	<3	Normal	+ve	+ve	+ve	Normal
60	M/54	Dominant	Colles' fracture	3-6	Increased	+ve	+ve	+ve	Normal

* +ve denotes positive, -ve negative

Table 2
Blood flow (first) phase of the three-phase bone scintigraphy (TPBS) and duration of complex regional pain syndrome (CRPS)

Duration of CRPS (months)*	Blood flow (first) phase of TPBS, n=60	
	Positive	Negative
<3	26	0
3-6	18	2
>6	10	4
Total	54 (90%)	6 (10%)

* The difference between the groups of <3 months and >6 months is significant (p<0.05, Chi squared test)

Table 3
Sympathetic skin response (SSR) and duration of complex regional pain syndrome (CRPS)

Duration of CRPS (months)*	SSR, n=60	
	Normal	Abnormal
<3	23	3
3-6	18	2
>6	3	11
Total	44 (73%)	16 (27%)

* The differences between groups >6 months and (i) 3-6 months and (ii) <3 months are significant (p<0.05, Chi squared test)

popular.^{3,15,16,20,21,23,27-29} Diffuse increased uptake and particularly increased periarticular uptake involving multiple joints of the affected extremity contributes to positive images. The sensitivity of TPBS in diagnosing CRPS varies from 54 to 100%.^{20,23} In the present study, the delayed (third) phase is the most reliable for the purpose of confirming the clinical diagnosis, which is consistent with other investigations reporting 94 to 100% sensitivity.^{20,29} However, the study by Kozin et al.¹⁶ reported a sensitivity of 60%. This disparity may have been due to differences in clinical criteria adopted by Kozin et al.¹⁶ for diagnosing CRPS, which very likely less strict. The wide range of reported sensitivity values could also be due to sampling errors, lack of controls, or difference in interpretation of scintigraphic images by radiologists.

The blood flow (first) phase of the bone scintigraphy is least sensitive and may only reveal diffusely increased uptake in patients with early stages of CRPS. Of our 6 patients with negative blood flow phase, 4 presented after 6 months and 2 within 3 to 6 months; no patients presenting within 3 months had a negative scan (p<0.05, Chi squared test; Table 1). It has

Table 4
Sympathetic skin response (SSR) and sweating abnormalities

SSR	Sweating		
	Normal	Increased	Decreased
Normal	24	18	2*
Abnormal	4	0	12*
Total	28	18	14

* The difference in proportions are significant (p<0.001, Chi squared test)

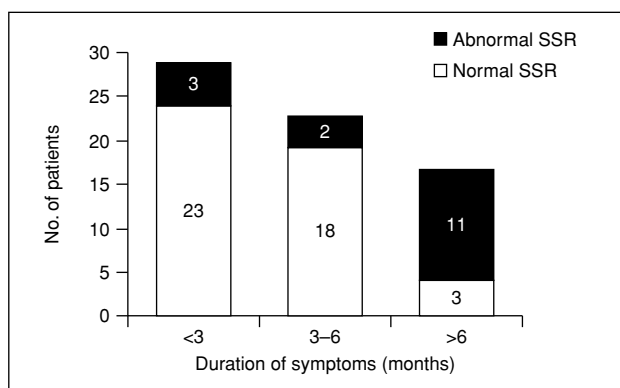


Figure 3 Association between the duration of symptoms and sympathetic skin response (SSR).

been reported that the mean duration of symptoms in CRPS patients with a positive scan was 2 months, compared to 19 months for those in whom it was negative.²² By comparing the TPBS in patients with CRPS before and after sympathetic block, a significant association has been noted between increased blood flow in the first phase and increased bone uptake in the third phase.²⁸ Thus increased early blood flow may in some way be responsible for the increased uptake in the delayed phase. In CRPS, maximal vascular flow occurs during the first 20 weeks, so the increased periarticular uptake should also be maximal during the initial stages.

Sympathetic dysfunction is believed responsible for the pathogenesis of CRPS, but there is no objective test or other means of making a firm diagnosis.^{5,6} To develop such an objective test to assess sympathetic dysfunction in patients with CRPS, SSR of both hands was measured in all 60 patients. The unaffected sides revealed a normal response in all patients, indicating that there was no systemic dysautonomia. SSR is a transient change in the electrical potential of the

skin, reflexively evoked by a variety of internally generated or externally applied stimuli. When elicited by electrical stimulation, the response uses an arc, which includes large myelinated sensory fibres as its afferent limb, central relays and efferent sympathetic pre- and post-ganglionic nerve fibres, which activate the eccrine sweat glands in the skin.²⁵

The stage of disease appears to have a significant association with the SSR: patients who presented late (>6 months post symptom onset) had a significantly higher rate of abnormal results ($p < 0.05$, Table 3 and Fig. 3). Sympathetic activity is highest during the initial stages of CRPS and may decrease during later stages and hence manifest as an abnormal SSR.²⁴ It has shown that affected/normal hand amplitude ratios of SSR were significantly lower in the early stages of CRPS; abnormal SSR may be associated with autonomic disturbance in CRPS patients.¹⁸ A report examining SSR in 12 patients with RSD has shown normal SSR in 5, lower SSR amplitude than the contralateral normal side in 3, and absence of SSR in 4.¹⁹ Other report has showed SSR abnormalities in 15 of 24 patients with RSD and found these correlate

with the severity of the dystrophy.⁴

In the present study, 12 (75%) of the 16 patients with abnormal SSR had associated decreased sweating, compared with 2 (4.5%) of the 44 patients with normal SSR; this difference in proportions was statistically significant ($p < 0.001$, Chi squared test; Table 4). Thus, the SSR appears to be a specific test of skin sympathetic fibres, but other manifestations of sympathetic dysfunction such as abnormalities of vascular tone (a cause of CRPS) may escape detection.

CONCLUSION

TPBS is a very sensitive corroborative test to confirm the clinical suspicion of CRPS. Diagnosis based on TPBS is most accurate during the initial stages and less so in patients presenting late. SSR, though not very sensitive, can be used to assess sympathetic dysfunction in patients with associated sweating abnormality and to confirm late cases of CRPS when TPBS is not reliable.

REFERENCES

- Mitchell SW, Morehouse CR, Keen WW. Gunshot wounds and other injuries of the nerves. Philadelphia: JB Lippincott; 1864.
- Koman L, Poching GG, Smith TL. Complex regional pain syndrome. Reflex sympathetic dystrophy and causalgia. Green's operative hand surgery. Vol 1, 4th Ed. 1999:636–66.
- Lee GW, Weeks PM. The role of bone scintigraphy in diagnosing reflex sympathetic dystrophy. *J Hand Surg Am* 1995;20:458–63.
- Rommel O, Tegenthoff M, Pern U, Strumpf M, Zenz M, Malin JP. Sympathetic skin response in patients with reflex sympathetic dystrophy. *Clin Auton Res* 1995;5:205–10.
- Sunderland S. Pain mechanisms in causalgia. *J Neurol Neurosurg Psychiatry* 1976;39:471–80.
- Bej MD, Schwartzman RJ. Abnormalities of cutaneous blood flow regulation in patients with reflex sympathetic dystrophy as measured by laser Doppler fluxmetry. *Arch Neurol* 1991;48:912–5.
- Stanton-Hicks M, Janig W, Hassenbusch S, Haddox JD, Boas R, Wilson P. Reflex sympathetic dystrophy: changing concepts and taxonomy. *Pain* 1995;63:127–33.
- Atkins RM, Duckworth T, Kanis JA. Algodystrophy following Colles' fracture. *J Hand Surg Br* 1989;14:161–4.
- Atkins RM, Duckworth T, Kanis JA. Features of algodystrophy after Colles' fracture. *J Bone Joint Surg Br* 1990;72:105–10.
- Atkins RM, Duthie RB. Algodystrophy (reflex sympathetic dystrophy or sudeck's atrophy). *Oxford textbook of medicine*. 2nd ed. Oxford: Oxford University Press; 1987:89–91.
- Bacorn RW, Kurtzke JF. Colles' fracture: a study of two thousand cases from the New York State Workmen's Compensation Board. *J Bone Joint Surg Am* 1953;35:634–58.
- Barron R, Janig W. Clinical characteristics of patients with complex regional pain syndrome in Germany with special emphasis on vasomotor function. Reflex sympathetic dystrophy: a reappraisal. *Progress in pain research and management*. Vol VI. IAS Press; 1995:25–48.
- Holder LE, Mackinnon SE. Reflex sympathetic dystrophy in the hands: clinical and scintigraphic criteria. *Radiology* 1984;152:517–22.
- Kleinert HE, Cole NM, Wayne L, Harvey R, Kutz JE, Atasoy E. Post-traumatic sympathetic dystrophy. *Orthop Clin North Am* 1973;4:917–27.
- Kozin F, Genant HK, Bekerman C, McCarty DJ. The reflex sympathetic dystrophy syndrome. II. Roentgenographic and scintigraphic evidence of bilaterality and of periarticular accentuation. *Am J Med* 1976;60:332–8.
- Kozin F, Soin JS, Ryan LM, Carrera GF, Wortmann RL. Bone scintigraphy in the reflex sympathetic dystrophy syndrome. *Radiology* 1981;138:437–43.
- Arner S. Intravenous phentolamine test: diagnostic and prognostic use in reflex sympathetic dystrophy. *Pain* 1991;46:17–22.

18. Chan RC, Chuang TY, Chiu FY. Sudomotor abnormalities in reflex sympathetic dystrophy. *Zhonghua Yi Xue Za Zhi (Taipei)* 2000;63:189–95.
19. Drory VE, Korczyn AD. The sympathetic skin response in reflex sympathetic dystrophy. *J Neurol Sci* 1995;128:92–5.
20. Mackinnon SE, Holder LE. The use of three-phase radionuclide bone scanning in the diagnosis of reflex sympathetic dystrophy. *J Hand Surg Am* 1984;9:556–63.
21. O'Donoghue JP, Powe JE, Mattar AG, Hurwitz GA, Laurin NR. Three-phase bone scintigraphy. Asymmetric patterns in the upper extremities of asymptomatic normals and reflex sympathetic dystrophy patients. *Clin Nucl Med* 1993;18:829–36.
22. Werner R, Davidoff G, Jackson MD, Cremer S, Ventocilla C, Wolf L. Factors affecting the sensitivity and specificity of the three-phase technetium bone scan in the diagnosis of reflex sympathetic dystrophy syndrome in the upper extremity. *J Hand Surg Am* 1989;14:520–3.
23. Davidoff G, Werner R, Cremer S, Jackson MD, Ventocilla C, Wolf L. Predictive value of the three-phase technetium bone scan in diagnosis of reflex sympathetic dystrophy syndrome. *Arch Phys Med Rehabil* 1989;70:135–7.
24. Drucker WR, Hubay CA, Holden WD, Bukovnic JA. Pathogenesis of post-traumatic sympathetic dystrophy. *Am J Surg* 1959;97:454–65.
25. Shahani BT, Halperin JJ, Boulu P, Cohen J. Sympathetic skin response—a method of assessing unmyelinated axon dysfunction in peripheral neuropathies. *J Neurol Neurosurg Psychiatry* 1984;47:536–42.
26. Valls-Sole J, Monforte R, Estruch R. Abnormal sympathetic skin response in alcoholic subjects. *J Neurol Sci* 1991;102:233–7.
27. Genant HK, Kozin F, Bekerman C, McCarty DJ, Sims J. The reflex sympathetic dystrophy syndrome. A comprehensive analysis using fine-detail radiography, photon absorptiometry, and bone and joint scintigraphy. *Radiology* 1975;117:21–32.
28. Hoffman J, Phillips W, Blum M, Barohn R, Ramamurthy S. Effect of sympathetic block demonstrated by triple-phase bone scan. *J Hand Surg Am* 1993;18:860–4.
29. Kline SC, Holder LE. Segmental reflex sympathetic dystrophy: clinical and scintigraphic criteria. *J Hand Surg Am* 1993;18:853–9.